


Hand-Held Instruments

#18224 Caro Manipulator



My Technique

Dr Bruno Decay
(Vic-en-Bigorre, France)



Preventive and therapeutic external massage of thin LASIK flap

Although a thin LASIK flap minimizes the risk of postoperative corneal ectasia, sub-Bowman's keratomileusis can sometimes be associated with folds and microstriae. This may require retreatment and is viewed unfavorably by patients. **Intraoperative external massage allows refractive surgeons to reduce the risk of this complication.**

Dr Bruno Decay
Vic Montaner LASIK center, Vic-en-Bigorre, France

I) THERAPEUTIC EXTERNAL MASSAGE: PUBLISHED RESULTS

Fox et al. (1) reported their results on 25 consecutive eyes with loss of best corrected visual due to post-LASIK flap microstriae. **In 96% of eyes, therapeutic flap massage with the Caro Manipulator was an effective treatment of symptomatic flap microstriation after LASIK.**

That study has dramatically changed my practice: I sometimes had microstriae with thin LASIK flaps, but now that I routinely perform external massage with the Caro Manipulator at the time of surgery, I no longer experience such complications.

II) PREVENTIVE EXTERNAL MASSAGE: MY TECHNIQUE

External massage is applied once the LASIK flap is repositioned after excimer treatment. It requires the use of a dedicated hand-held instrument, the **"Caro Manipulator" (Moria SA, Antony, France)**¹.

Material:

The Caro Manipulator has a hemispherical, **highly polished tip to avoid damage to the epithelium** during external flap massage.

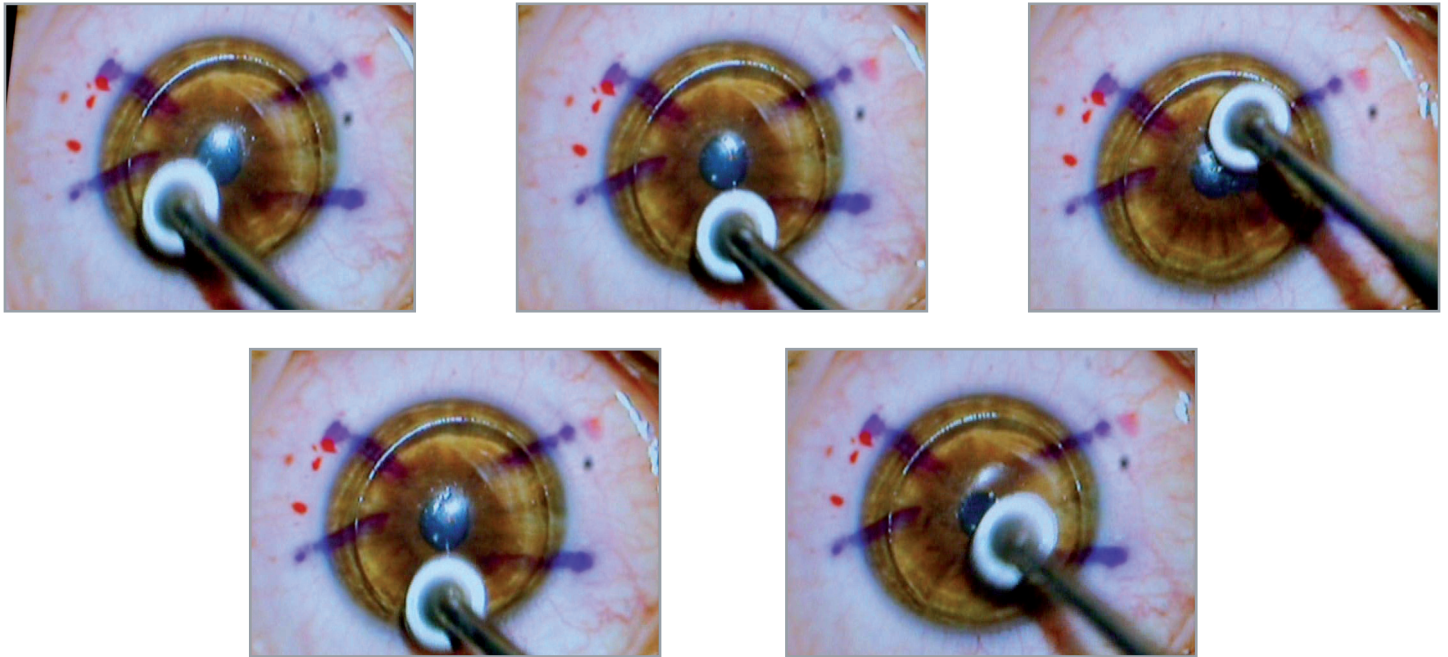


Step 1: Flap repositioning after laser treatment

A nasal-hinged LASIK flap has been created using the One Use-Plus SBK automated microkeratome (Moria SA, Antony, France). It is important to allow sufficient time for complete drying in order to avoid flap dislodgment during the external massage.

Step 2: External flap massage to prevent from microstriae

We demonstrate here a routine external massage during the surgery to avoid any flap microstriae. The smooth tip of the Caro Manipulator is applied over the entire flap surface, taking care not to dislodge edges.



III) CONCLUSION

External flap massage using the Caro Manipulator is a simple technique that should be part of every refractive practice, not only as a therapeutic but also as a preventive measure.

Key-words:

LASIK flap, external massage, Caro Manipulator

Reference:

- ¹ Fox ML, Harmer E. Therapeutic flap massage for microstriae after LASIK. Treatment technique and implications. *J Cataract Refract Surg.* 2004;30:369-373

Dr. Decay has no financial interest in the product mentioned nor is he a paid consultant for Moria.

To obtain more information



MORIA SA

15, rue Georges Besse
92160 Antony
FRANCE
Phone: +33 (0) 1 46 74 46 74
Fax: +33 (0) 1 46 74 46 70
www.moria-surgical.com

MORIA Inc

1050 Cross Keys Drive
Doylestown, PA 18902
USA
Phone: (800) 441 1314
Fax: +1 (215) 230 7670
www.moria-surgical.com

MORIA JAPAN KK

Inami Bldg. 6F
3-24-2 Hongo Bunkyo-ku
Tokyo 113-0033
JAPAN
Phone: +81 3 5842 6761
Fax: +81 3 5842 6762
www.moriajapan.com

MORIA in CHINA

Moria Commercial (China) Co. Ltd
Rm H, I, 6FL, Kai Li Building
N° 432 Huai Hai West Road
Shanghai 200052
CHINA
Phone: +86 21 5258 5066
Fax: +86 21 5258 5067
www.moria-surgical.com.cn

Moria
Leading Innovations in Ophthalmology